

Multislice CT angiography in the evaluation of hepatic vascular anatomy in potential right lobe donors

Suzan Şaylısoy, Çetin Atasoy, Sadık Ersöz, Kaan Karayalçın, Serdar Akyar

PURPOSE

To assess the role of multislice CT angiography in the evaluation of arterial, hepatic and portal venous variations in potential right lobe donors.

MATERIALS AND METHODS

Fifty-two potential liver donors (28 females, 24 males), underwent CT angiography in the arterial and portal venous phases with an eight-row CT scanner. Two- and three-dimensional images were obtained from 1.25-mm-thick axial images with multiplanar reformatting, maximum intensity projection and volume rendering techniques. Both axial and two- and three-dimensional images were evaluated for possible variants of hepatic vasculature. In twelve operated patients, CT angiography results were compared with the results of surgery.

RESULTS

Of 52 patients, 40 had type I, five type III, two type II, three type IX, and two type V hepatic arterial anatomy. In 13 patients (25%), segment IV artery originated from the right hepatic artery. In 26 patients (50%), veins that drained segment V and/or VIII to the middle hepatic vein were larger than 5 mm. Twenty-five patients (48%) had 28 accessory hepatic veins larger than 3 mm; 23 of these drained to the inferior vena cava more than 4 cm caudal to the right hepatic vein-vena cava junction. Three patients (6%) had trifurcation and one patient (2%) had quadrifurcation of the main portal vein. In two patients (4%), the right posterior portal vein arose directly from the main portal vein before its bifurcation. CT angiography findings showed one-to-one correlation with surgery in the 12 operated patients.

CONCLUSION

Multislice CT angiography can successfully show the relevant hepatic vascular variations in potential liver donors.

Key words: • tomography, spiral computed • imaging, three-dimensional • variation • vasculature • liver transplantation

Liver transplantation is a successful treatment option, with its capacity for increasing the one year-life expectancy by more than 80% in chronic liver disease and liver failure (1). One of the most important problems experienced in liver transplantation is the rapid increase in the difference between the number of patients in need for liver transplantation and the number of available cadaver livers (2). For that reason, liver transplantation from a living donor has been introduced as an alternative to liver transplantation from cadavers. Liver transplantation from a living donor has some advantages such as the increased number of organs available for transplantation, chance of performing the operation in elective conditions, and elimination of the waiting period for the recipient for a cadaver organ. These factors decrease morbidity, mortality and cost. Shortened period of cold ischemia and obtaining the liver from a living donor are the other advantages (3). Right lobe liver transplantation is performed in adults, as opposed to pediatric population, since left lobe lateral segment graft fails to meet the metabolic needs of the adult recipient (4).

The main purpose of pre-operative imaging in liver transplantation is to expose the arterial and venous vascular map (4). It is necessary to image the vascular structures properly prior to transplantation due to the complex nature of liver vascular anatomy and its frequent variations. CT is a useful method not only in the determination of hepatic arterial anatomy, the source of the segment IV artery, hepatic venous anatomy, accessory hepatic veins and portal vein variations, but also in the evaluation of bile ducts, liver volume and steatosis in the potential donor (1).

The multislice (multidetector) CT angiography technique, which has been spreading widely for the last six years, is a method that allows faster volume imaging of the whole liver with thinner slices in high spatial resolution within one breath-hold period, when compared with the CT devices with a single detector row. The isotropic two- and three-dimensional images, which were obtained by using thin slices rendered possible CT angiography of the relatively thinner venous structures. In this study, the ability of multislice CT angiography to image venous variations that might cause contraindication to transplantation or make the surgical operation more difficult on potential liver donors, and the frequency of these variations were investigated.

Materials and methods

A total of 52 adult patients (28 females, 24 males), with an age range between 18 and 58 (average age, 30.5 years), who were potential donors for liver transplantation were evaluated for hepatic arterial, hepatic and portal venous anatomy and possible variations by using a CT device with an eight-row scanner (Light Speed Ultra, General Electric, Milwaukee, Wisconsin, USA). The scanning parameters were 8×1.25 mm collimation,

From the Departments of Radiology, (S.Ş. ✉, Ç.A., S.A.), and General Surgery (S.E., K.K.) Ankara University School of Medicine, Turkey.

Received 08 August 2004; revision requested 08 August 2004; revision received 12 December 2004; accepted 21 December 2004.

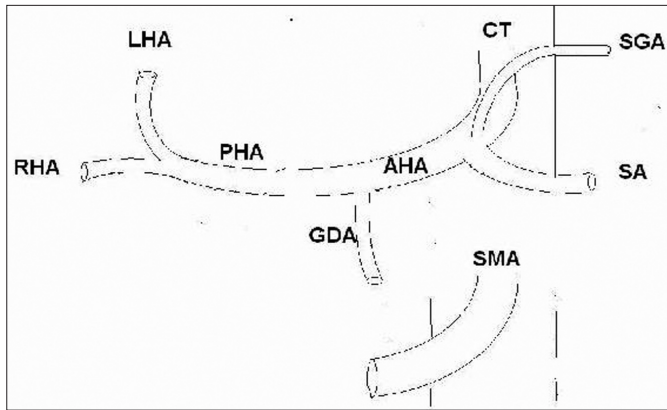


Figure 1. Type I (conventional anatomy). The main hepatic artery (AHA) originating from celiac truncus (CT) gives off the gastroduodenal artery (GDA) and the proper hepatic artery (PHA), and the proper hepatic artery splits into the left (LHA) and the right (RHA) hepatic arteries (SGA: left gastric artery, SA: splenic artery, SMA: superior mesenteric artery).

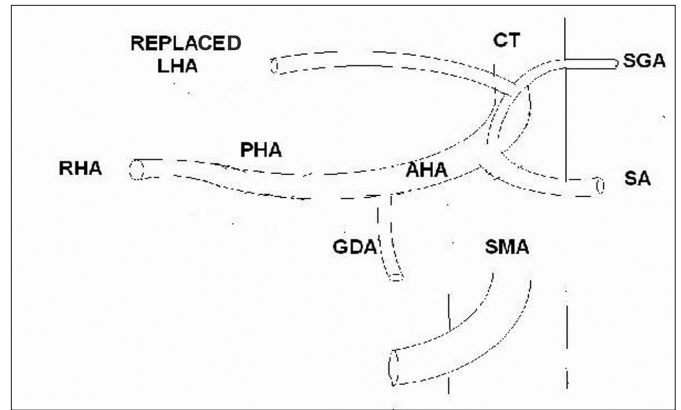


Figure 2. Type II (replaced left hepatic artery). The left hepatic artery (LHA) originates from the left gastric artery (SGA).

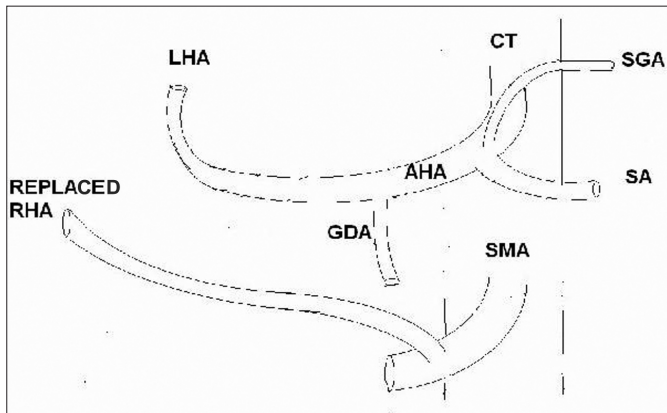


Figure 3. Type III (replaced right hepatic artery). The right hepatic artery (RHA) originates from the superior mesenteric artery (SMA).

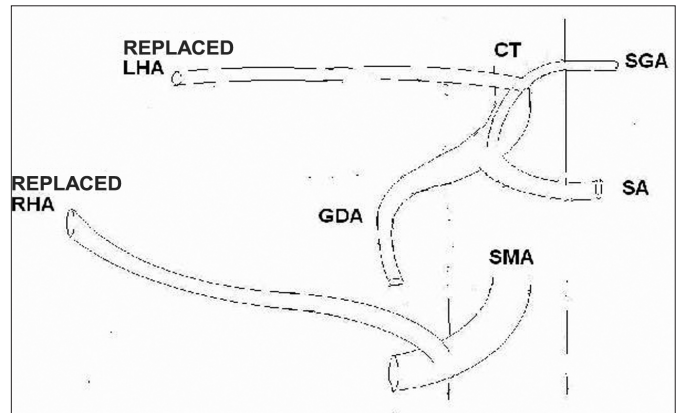


Figure 4. Type IV (the combination of replaced right and replaced left hepatic arteries). The replaced right hepatic artery (RHA) originating from the superior mesenteric artery (SMA) and the replaced left hepatic artery (LHA) originating from the left gastric artery (SGA) are visible.

1.25 mm slice thickness for axial images, 0.6 mm reconstruction interval, 0.5 s tube rotation period and 140 kV, 330 mA standard reconstruction algorithm. The intravenous contrast material containing 350 mg of iodine per ml was injected through an antecubital vein with a total volume of 2 ml/kg of patient's weight and an injection rate of 4-6 ml/s by using an automatic injector. The arterial phase scanning was started when maximum aortic enhancement was reached at the coeliac truncus level by using an automatic bolus-tracking program (SmartPrep). The portal phase images were obtained 35 seconds after the commencement of the arterial phase. On a separate workstation, two-dimensional (2D) multiplanar reformatted images and three-dimensional (3D) images with maximum intensity projection (MIP) and volume rendering (VR) techniques were obtained from thin axial images.

The images were evaluated for hepatic arterial, portal and hepatic venous variations.

Hepatic arterial anatomy was evaluated with the images on coronal oblique plane that were obtained by using VR and MIP techniques in addition to the axial images. The hepatic arterial anatomy of the patients was classified according to the system defined by Michels (5). In the conventional anatomy defined as type I according to Michels classification (Figure 1), the main hepatic artery originates from coeliac truncus, gives off the gastroduodenal artery and the proper hepatic artery, the proper hepatic artery continues as the right hepatic artery after giving off the left hepatic artery and then the right hepatic artery splits into its anterior and posterior branches (5). The left hepatic artery splits into branches that feed segments II and III. Segment IV is fed by the branch or

branches originating from the right, left, or the proper hepatic artery. The left hepatic artery originating from the left gastric artery (replaced left hepatic artery) is defined as type II (Figure 2), the right hepatic artery stemming from the superior mesenteric artery (replaced right hepatic artery) as type III (Figure 3) and co-existence of both situations is defined as type IV (Figure 4). The left lobe is also fed by the accessory left hepatic artery originating from the left gastric artery in type V variation (Figure 5), and right lobe is also fed by accessory right hepatic artery originating from the superior mesenteric artery in type VI variation (Figure 6). Both the left and right accessory artery exist in type VII (Figure 7); the replaced right hepatic artery and the accessory left hepatic artery or the accessory right hepatic artery and the replaced left hepatic artery co-exist in type VIII (Figure 8). The hepatic truncus originates from the superior mesenteric artery in type

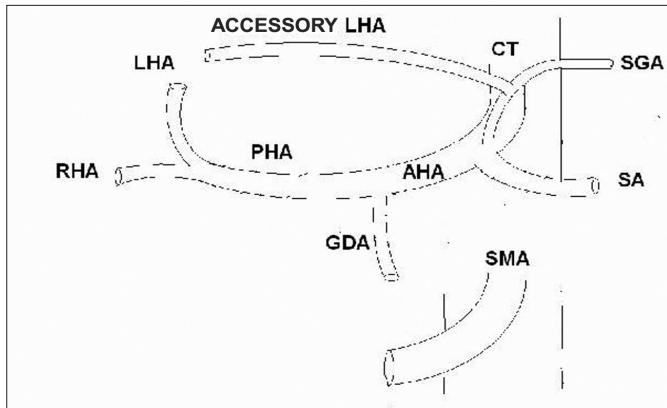


Figure 5. Type V (accessory left hepatic artery). The left lobe is fed by both the left hepatic artery (LHA) originating from the proper hepatic artery (PHA) and the accessory left hepatic artery originating from the left gastric artery (SGA).

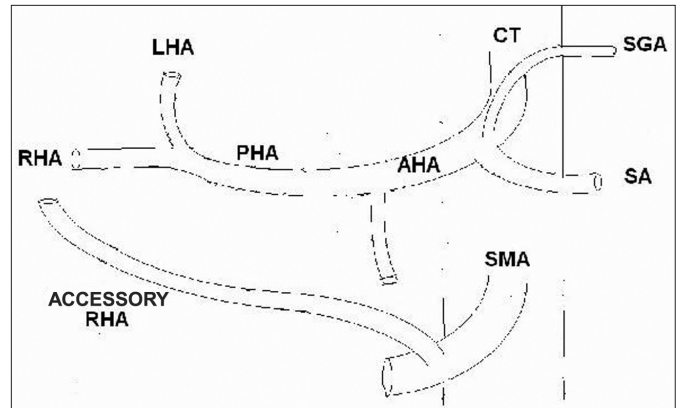


Figure 6. Type VI (accessory right hepatic artery). The right lobe is fed by both the right hepatic artery (RHA) originating from the proper hepatic artery (PHA) and the accessory right hepatic artery originating from the superior mesenteric artery (SMA).

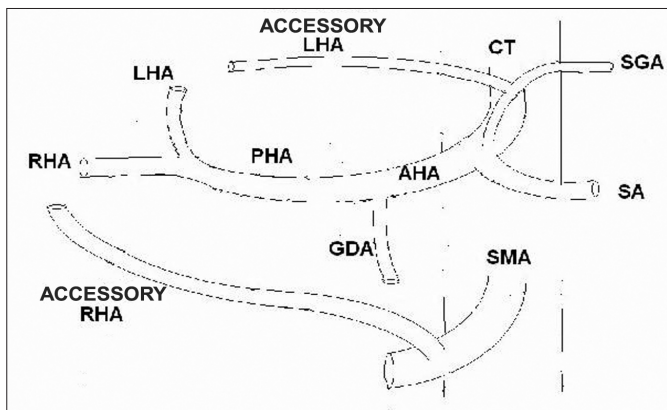


Figure 7. Type VII. The right (RHA) and left hepatic arteries (LHA) originating from the proper hepatic artery (PHA) are visible as well as the accessory left hepatic artery originating from the left gastric artery (SGA) and the accessory right hepatic artery originating from the superior mesenteric artery (SMA).

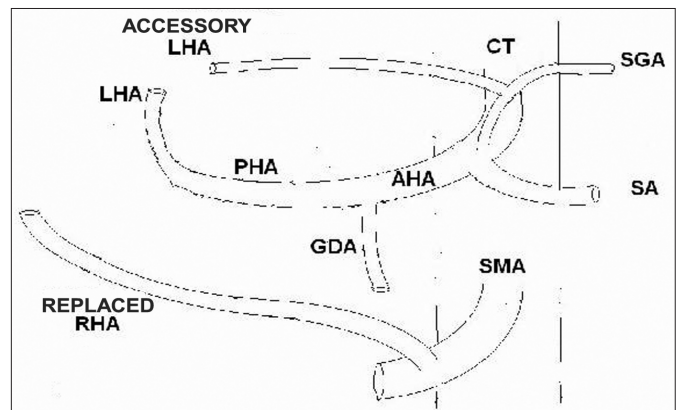


Figure 8. Type VIII. The replaced right hepatic artery (RHA) originating from the superior mesenteric artery (SMA) and the accessory left hepatic artery (LHA) originating from the left gastric artery (SGA) are visible as two variations. In this type, the replaced left hepatic artery may be accompanied by the accessory right hepatic artery alternatively.

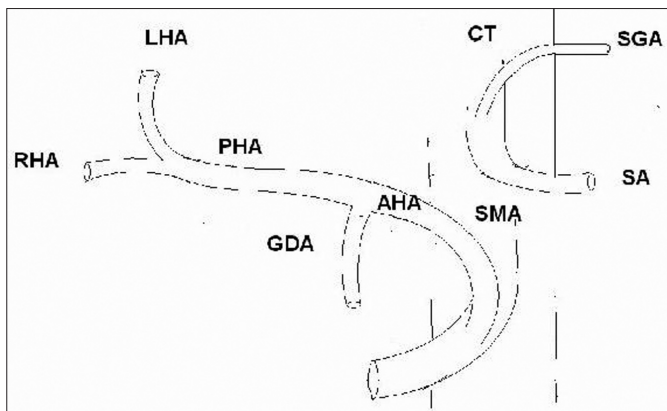


Figure 9. Type IX. The main hepatic artery (AHA) is originating from the superior mesenteric artery SMA.

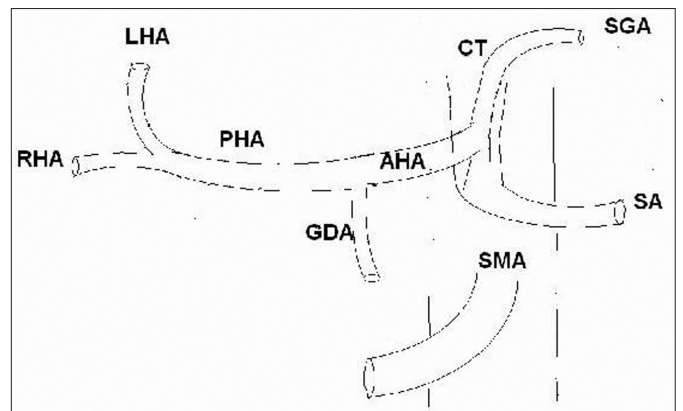


Figure 10. Type X. The main hepatic artery (AHA) is originating from the left gastric artery (SGA).

IX (Figure 9) and from the left gastric artery in type X (Figure 10) (6, 7). In addition to the classification of the hepatic arterial anatomy, the arteries from which the arteries feeding seg-

ment IV originated were determined and the distance between the origin of the segment IV artery and the origin of the right hepatic artery was measured on oblique coronal MIP images when

the dominant artery that fed segment IV originated from the right hepatic artery (Figure 11).

The variations in the hepatic veins were evaluated with axial images, VR

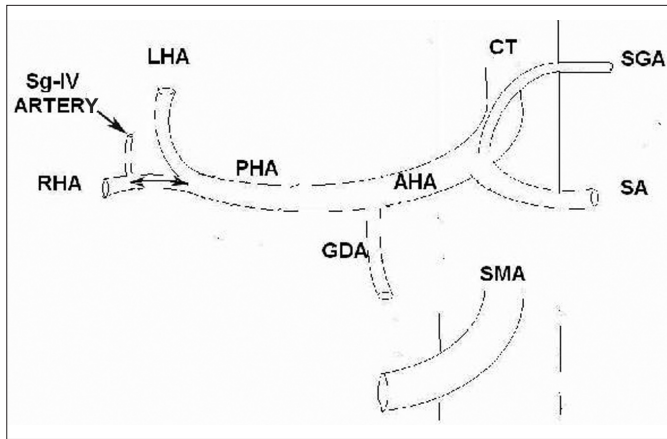


Figure 11. Segment IV artery originating from the right hepatic artery. The distance between the origin of the segment IV artery and the origin of the right hepatic artery was measured as shown in the drawing.

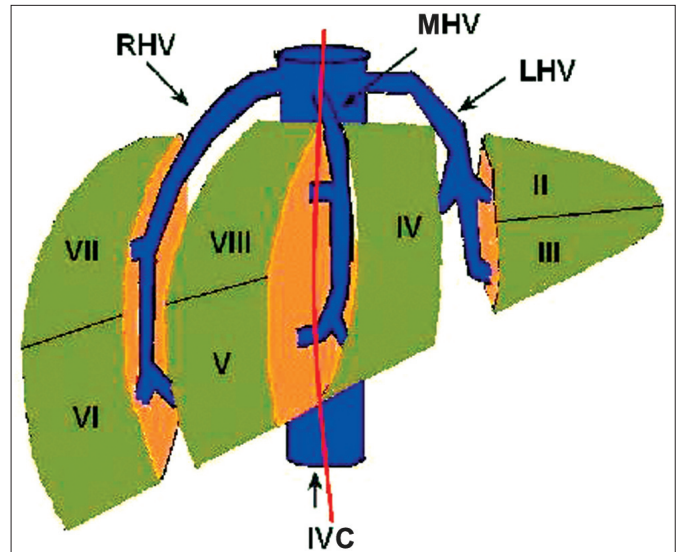


Figure 12. The segmental anatomy of the liver and hepatic venous drainage of the segments on the right anterolateral oblique view. Veins of segments V and/or VIII larger than 5 mm that move along the presumed hepatectomy plane (red line) that is expected to pass 1 cm to the right of the middle hepatic vein (MHV) were examined in the potential right lobe donors. (RHV: right hepatic vein, LHV: left hepatic vein, IVC: inferior vena cava.)

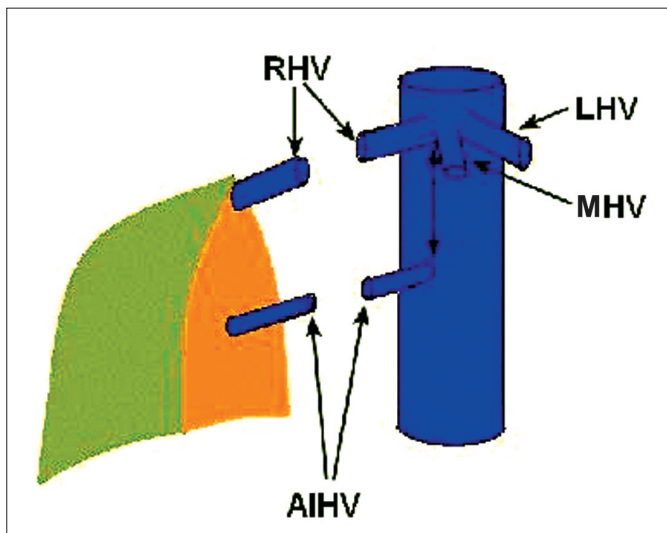


Figure 13. The right accessory inferior hepatic vein (AIHV). In the presence of the right accessory inferior hepatic vein, the diameter of this vein and the distance between the point where it drains into the IVC and the point where the right hepatic vein (RHV) opens into the inferior vena cava was measured as shown in the drawing. (MHV: middle hepatic vein, LHV: right hepatic vein.)

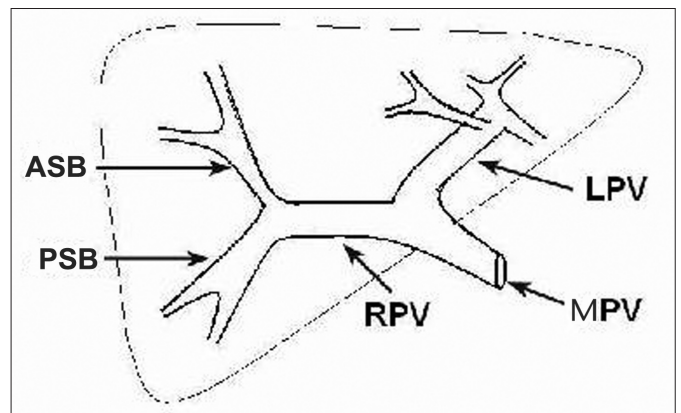


Figure 14. Normal portal vein anatomy. The main portal vein (MPV) splits into the right (RPV) and left (LPV) portal veins at the portal hilum, the right portal vein into its anterior (ASB) and rear (PSB) sectorial branches, and the left portal vein into the branches that feed segments II, III and IV.

images and MIP images on axial and oblique axial planes. In the hepatic venous system, presence of a vein larger than 5 mm that moves along the planned hepatectomy plane and drains segment V or VIII into the middle hepatic vein was examined (Figure 12). In addition, presence of the right accessory inferior hepatic vein was examined; the diameters of the detected accessory inferior hepatic veins and the distance between the point where they open into the inferior vena cava on the coronal plane and to the right hepatic vein-inferior vena cava junction was measured (Figure 13).

Portal vein anatomy was evaluated

with axial, VR and MIP images on the oblique coronal plane. In the classic anatomic pattern (Figure 14), the main portal vein bifurcates into the right and left portal veins in the liver hilum, and then the right portal vein splits into its anterior and posterior sectorial branches and the left portal vein into the branches that feed segments II, III and IV (8). In the portal venous system, the possible variations that may effect the transplantation surgery such as trifurcation (Figure 15) or quadrifurcation (Figure 16) of the main portal vein, separate origin

of the right posterior sectorial branch from the main portal vein (Figure 17) were evaluated.

CT findings and intraoperative findings were compared in 12 patients who were operated on as accepted donors.

Results

According to Michels classification, 40 patients (76%) had conventional arterial anatomy (type I) (Figure 18). two (4%) of the remaining patients had type II (Figure 19), five (10%) had type III (Figure 20), two (4%) had type

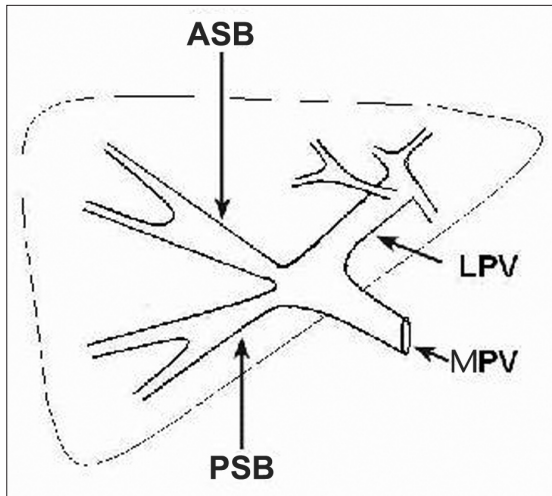


Figure 15. Trifurcation of the portal vein. The main portal vein splits into the left portal vein and the right anterior and right posterior sectoral branches. (ASB: anterior sectoral branch, PSB: posterior sectoral branch, LPV: left portal vein, MPV: main portal vein.)

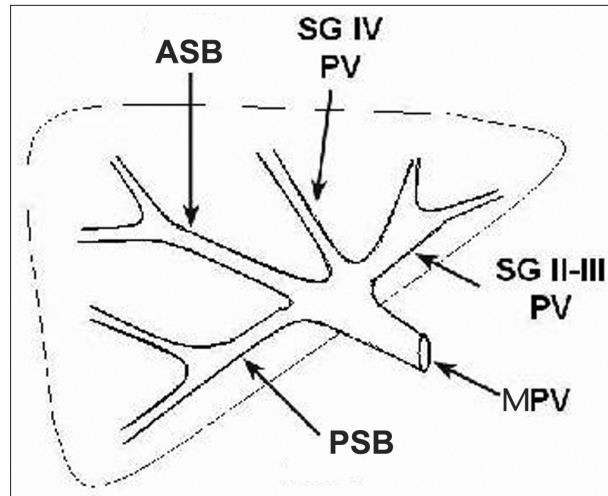


Figure 16. Quadrifurcation of the portal vein. The main portal vein splits into the branches that open into segments II, III and segment IV and into the right anterior and right posterior sectoral branches. (ASB: anterior sectoral branch, PSB: posterior sectoral branch, PV: portal vein, MPV: main portal vein.)

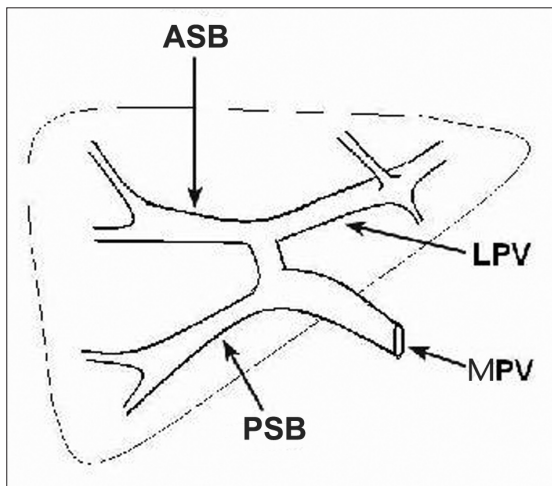


Figure 17. Separate origin of the right posterior sectoral branch from the main portal vein. (ASB: anterior sectoral branch, PSB: posterior sectoral branch, LPV: left portal vein, MPV: main portal vein.)

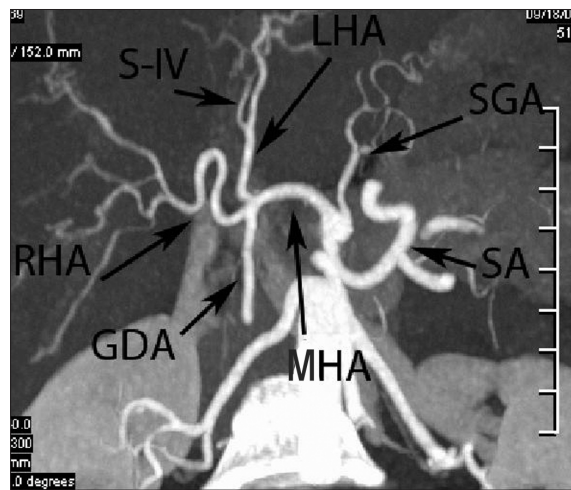


Figure 18. MIP image on the coronal oblique plane. The celiac artery and its branches (SA: splenic artery, LGA: left gastric artery, MHA: main hepatic artery) and the branching pattern of the hepatic artery into the gastroduodenal artery (GDA), the right hepatic artery (RHA) and the left hepatic artery (LHA). Segment IV artery (S-IV) is originating from the left hepatic artery.

V and three (6%) had type IX hepatic arterial anatomy. Anatomic types IV, VI, VII, VIII and X were not found. Segment IV artery originated from the left hepatic artery in 39 patients (75%), and from the right hepatic artery in 13 (25%) (Figure 21). Segment IV artery originating from the proper hepatic artery was not seen. The average distance between the segment IV artery originating from the right hepatic artery and the origin of the right hepatic artery was 14 mm (range, 9-22 mm).

The most frequent variation found in the hepatic venous system was the right accessory inferior hepatic vein

and a total of 28 right accessory inferior or hepatic veins larger than 3 mm were detected in 25 (48%) patients (Figure 22). The distance of 23 (44%) of these veins to the right hepatic vein-inferior vena cava junction was more than 4 cm. There were hepatic vein branches larger than 5 mm that moved along the planned hepatectomy plane and drained the right lobe into the middle hepatic vein in 26 (50%) patients. The large vein was draining segment VIII in 22 of these patients (Figure 23). Both segments V and VIII were draining into the middle hepatic vein through the large veins.

Conventional portal vein anatomy was observed in 46 (88%) patients (Figure 24). Variations with surgical significance were present in the portal venous system of 6 (12%) patients. Three patients (6%) had trifurcation (Figure 25), one (2%) had quadrifurcation of the portal vein. The right posterior sectoral branch was originating from the main portal vein in two patients (4%) (Figure 25).

There was a one-to-one correlation between the CT angiography findings and the surgical findings in 12 patients who were operated on as accepted donors.

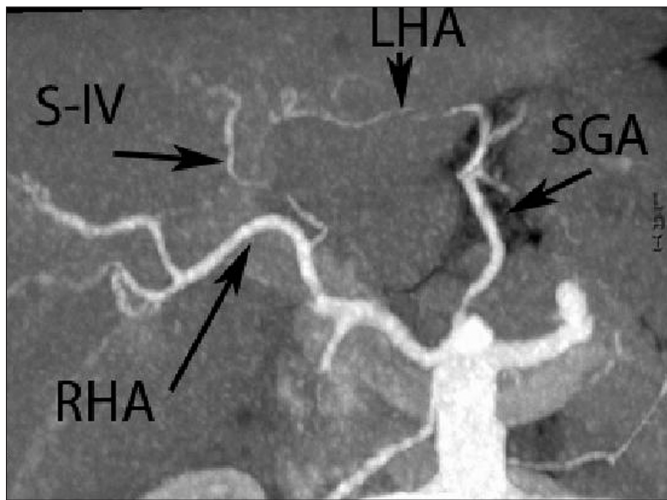


Figure 19. MIP image on coronal oblique plane. Type II hepatic artery anatomy. The left hepatic artery (LHA) is originating from the left gastric artery (LGA); the right hepatic artery (RHA) is originating from the main hepatic artery. The artery of segment IV (S-IV) is originating from the right hepatic artery. In this variation, the right hepatic artery should be clamped after the origin of segment IV artery during the right lobe transplantation.

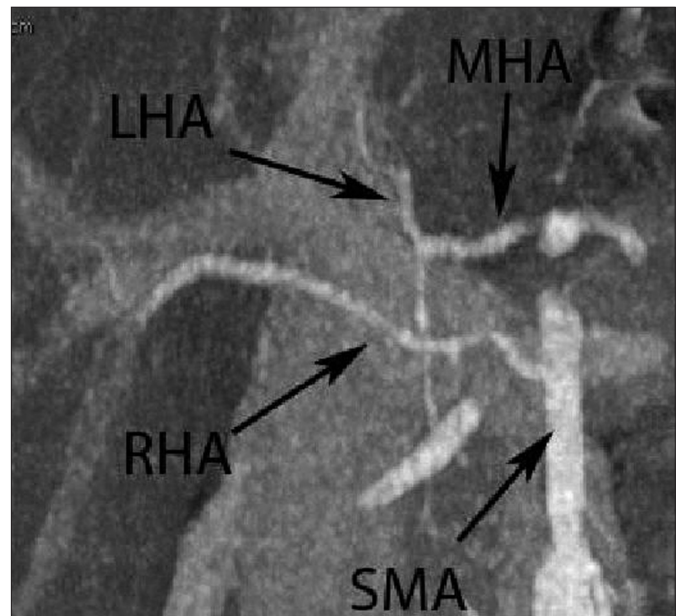


Figure 20. MIP image on the coronal oblique plane. Type III hepatic artery anatomy. The left hepatic artery (LHA) is originating from the main hepatic artery (MHA), and the right hepatic artery (RHA) from the superior mesenteric artery (SMA).

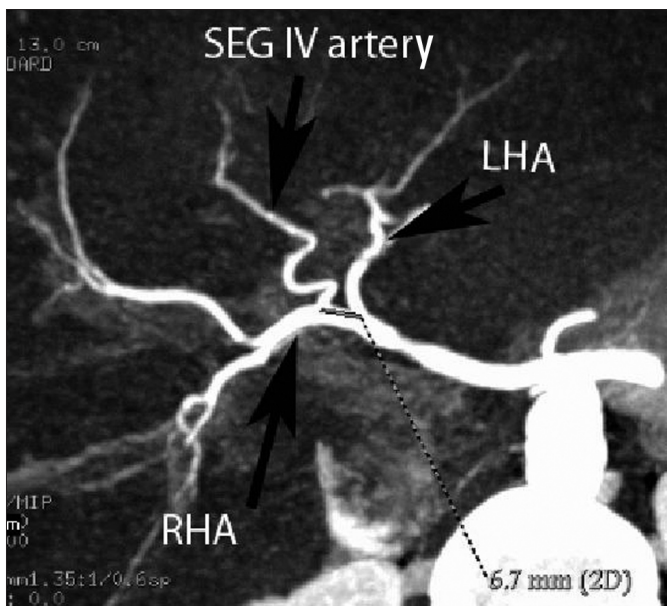


Figure 21. MIP image on the coronal oblique plane. Segment IV artery is originating from the right hepatic artery (RHA) 6.7 mm distal to the left hepatic artery (LHA) orifice.

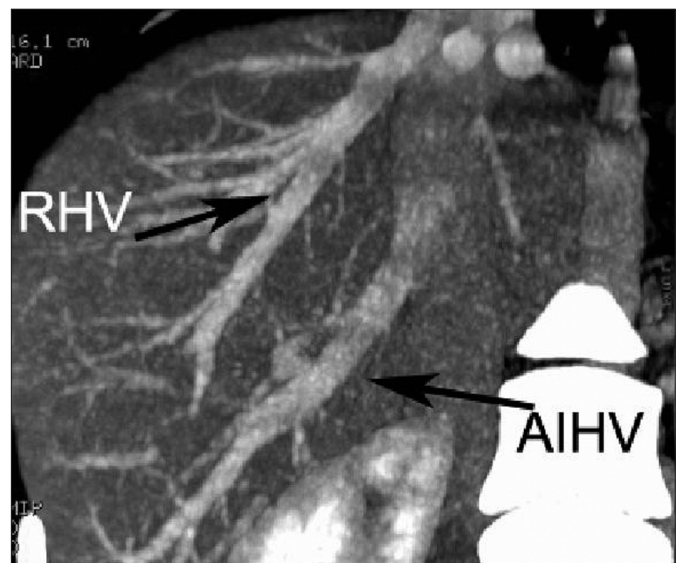


Figure 22. MIP image on the coronal oblique plane. Accessory inferior hepatic vein variation. The accessory inferior hepatic vein (AIHV) as large as the right hepatic vein (RHV) opens into the inferior vena cava more caudally than does the right hepatic vein.

Discussion

The high-speed volumetric scanning ability provided by multislice CT technology allows isotropic high quality two and three-dimensional imaging without artifacts by the use of thin slices. It has been reported that this method proved successful in determining the suitability of the potential liver donors for transplantation surgery (4, 6, 9, 10). Thanks to the examinations car-

ried out in arterial and portal phases, both arterial and venous mapping can be achieved and the possible venous variations that might hinder the operation or make it more difficult can be detected.

It is known that variations are relatively frequent in hepatic arterial system. Hepatic artery variations do not cause absolute contraindications for

transplantation surgery. However, being informed about these variations prior to the surgery is a factor that would simplify the surgery, decrease the rate of contraindications and improve the chance of technical success (11). Thanks to its ability to display anatomy from the desired plane and angle, CT angiography allows hepatic arterial variations to be detected. He-

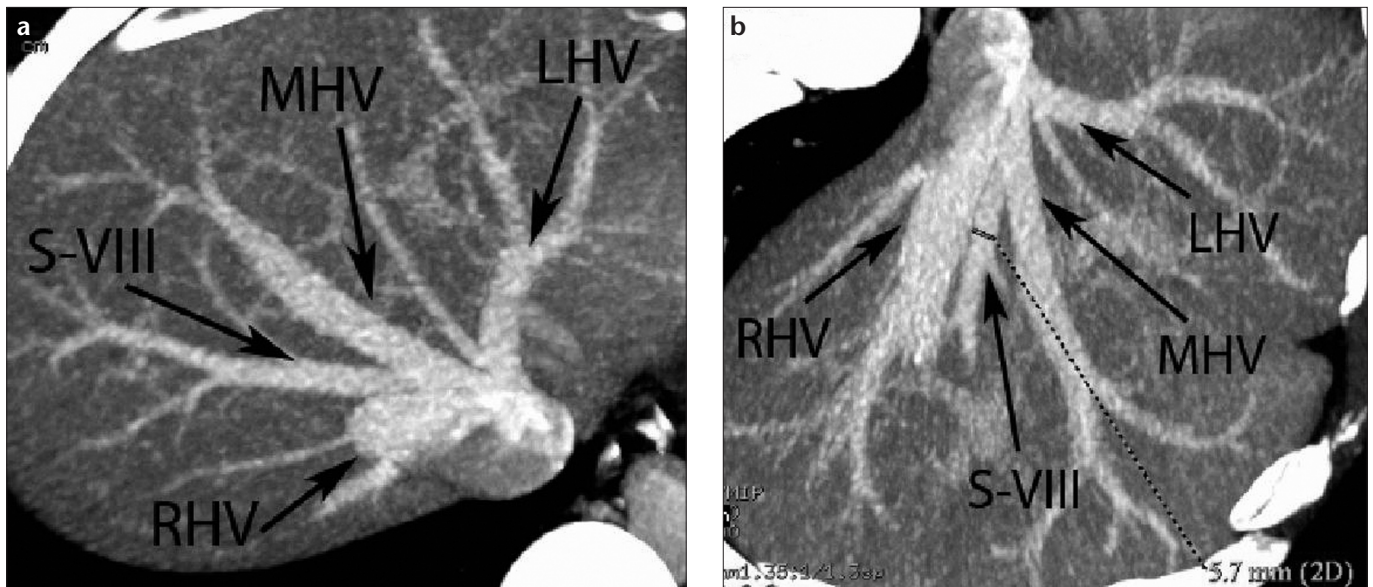


Figure 23. a, b. Large segment VIII vein opening into the main hepatic vein. **a.** Drainage of the right hepatic vein (RHV), the middle hepatic vein (MHV) and the left hepatic vein (LHV) into the inferior vena cava is visible on the MIP image on the coronal oblique plane. Only the proximal part of the right hepatic vein is visible from this angle. A large vein (S-VIII) that drains the segment VIII joins the main hepatic vein (MHV). **b.** Hepatic veins are opening into the inferior vena cava as seen on the MIP image obtained from a different angle. Segment VIII vein which is opening into the middle hepatic vein is 5.7 mm in diameter. This large vein that moves along the incision line should be reconstructed during the right lobe transplantation.

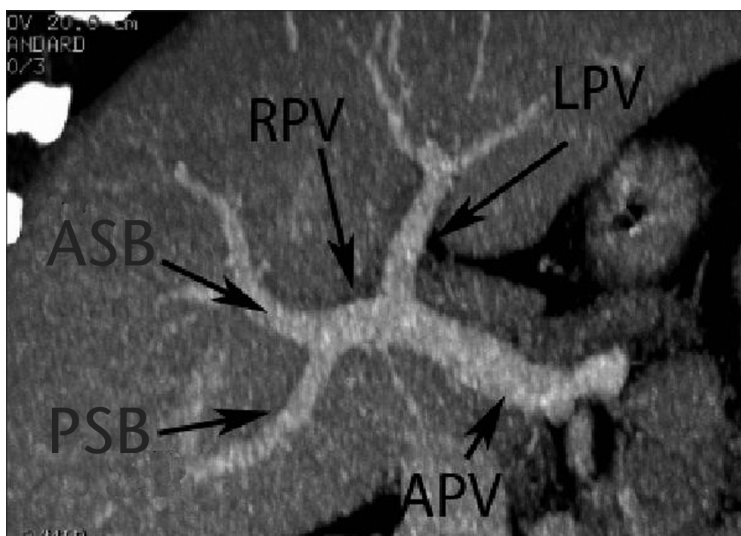


Figure 24. MIP image on the coronal oblique plane. Conventional portal vein anatomy. The right portal vein (RPV) and the left portal vein (LPV) are originating from the main portal vein (APV). The right portal vein splits into the anterior sectoral branch (ASB) that feeds segments V and VIII, and the posterior sectoral branch (PSB) that feeds segments VI and VII. The left portal vein splits into the branches that feed the left lobe.

hepatic arterial anatomy can be best evaluated in slices on the coronal oblique plane (12). In our study, we observed conventional (type I) hepatic artery in 76% of the patients. This rate was reported to be between 51% and 76% in the previous studies (13, 14). Ten percent of the patients had replaced right hepatic artery, 4% replaced left hepatic artery, 4% accessory left hepatic artery and 6% hepatic truncus originating from the superior mesenteric artery. These rates were 11%, 10%, 8%, and 9%, respectively, in Michels' study (5), and 8.7%, 3.8%, 10.7% and 2%, respectively, in the study carried out

by Covey et al. (7). Although anatomic types IV, VI, VII, VIII and X were not found in our patient group, the frequency of types IV, VI, VII, VIII and X was reported to be 0.5-1%, 1.5-7%, 1%, 2-3% and 0-0.5%, respectively (7).

The right lobe or left lobe lateral segment resection requires information about the origin of the segment IV artery as well. Although the dominant artery that feeds segment IV usually originates from the left hepatic artery, it may originate from the right hepatic artery in some patients. If segment IV artery originates from the right hepatic artery, the right hepatic artery should

be clamped after it gives off the segment IV artery. However, in right lobe transplantation, if the right hepatic arterial origin of the segment IV artery is not detected prior to the surgery and the right hepatic artery is clamped as it takes off from the proper hepatic artery, the left lobe medial segment that remains in the donor will develop ischemia and the metabolic needs of the donor may not be met during the regeneration process (10). Artery or arteries of segment IV can easily be located by means of multislice CT angiography (15). In our study, segment IV artery originated from the right

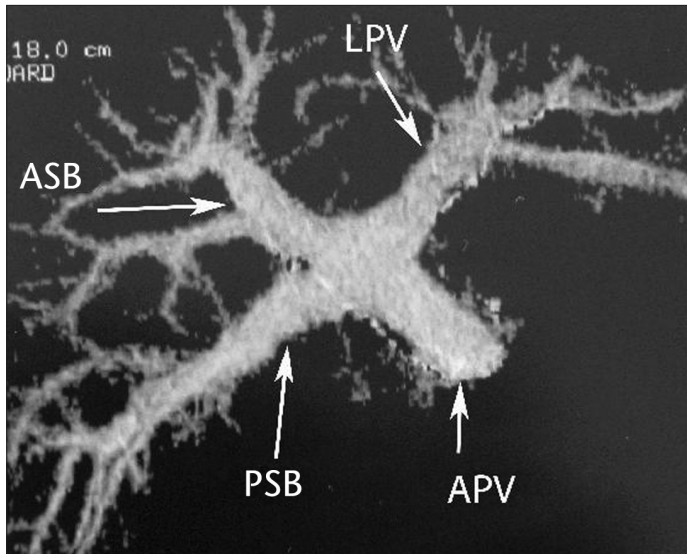


Figure 25. Volume-rendered image. Trifurcation variation in portal vein. Three branches are originating from the main portal vein (APV): the posterior sectoral branch (ASB) that feeds segments VI and VII, the anterior sectoral branch (PSB) that feeds segments V and VIII, the left portal vein (LPV) that feeds the left lobe. In this variation, anastomosis of the two portal veins is required during the right lobe transplantation.

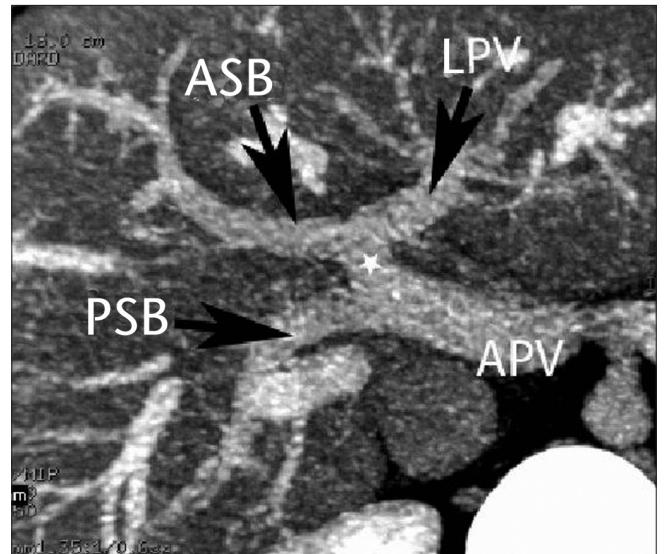


Figure 26. MIP image on the coronal oblique plane. The separate origin of the right posterior sectoral branch (PSB) from the main portal vein is visible. The right anterior sectoral branch (ASB) and the left portal vein (LPV) are originating from the same truncus (asterisk). In this variation, anastomosis of the two portal veins is also required during the right lobe transplantation.

hepatic artery in 25% of the patients. This condition was reported with significantly variable rates (6-62.5%) in other studies (4, 9). Guiney et al. reported the distance between the segment IV artery that originates from the right hepatic artery and the origin of the right hepatic artery to be 1.2 cm on average (9). In our series, this distance was 1.4 cm on average. Calculation of this distance will make surgeons' job easier during dissection.

In the right lobe transplantation, the hepatectomy line passes approximately 1 cm to the right side of the hepatic vein as a standard procedure. For that reason, it should be known whether an important vascular structure that moves along the hepatectomy plane is present. Under ideal surgical conditions, the entire venous drainage of segments IV and VIII should be done by the right hepatic vein. Relatively large hepatic veins in some patients drain segments V and/or VIII into the middle hepatic vein and they move along the planned hepatectomy plane. Veins of segments V and VIII that are larger than 5 mm and drain into the middle hepatic vein should be examined in preoperative CT angiography (15). In such cases, these veins should not be clamped but be reconstructed, or the hepatectomy plane should be changed.

When the veins are clamped without prior knowledge of these variations, ischemic necrosis occurs in the segments drained by these veins and this may lead to graft failure in the recipient. Hepatic venous anatomy and its variations can be best evaluated on the axial plane by using maximum intensity projection (MIP) method. In our study, half of the patients had hepatic veins larger than 5 mm that drained segments V and/or VIII into the middle hepatic vein.

Another variation in the hepatic venous system that should be known prior to transplantation surgery is the existence of the right accessory inferior hepatic vein. This variation occurs quite frequently and reported frequency is as high as 68% in the literature (2, 4, 12). Accessory hepatic veins drain the dorsal part of the liver (mainly segments VI and VII) (8). Accessory hepatic veins are necessary for the venous drainage of the transplanted right lobe (9, 15). If the accessory hepatic veins with a diameter of more than 3 mm are not located prior to the surgery and not reconstructed during the surgery, graft congestion and liver failure may develop as a result of venous drainage obstruction (2, 9). When a large accessory inferior hepatic vein is located, it is important to know the distance between the point where this vein opens

into the inferior vena cava and the right hepatic vein-inferior vena cava junction. A distance of more than 4 cm makes the surgery longer and more difficult (4). Almost half of the potential donors had accessory inferior hepatic veins larger than 3 mm, and the distance between the point where the accessory vein drains into the inferior vena cava and the right hepatic vein-inferior vena cava junction was more than 4 cm.

Portal venous anatomy can be best imaged on the coronal plane in CT angiography (2, 4). Some anatomic variations in the portal venous system cause contraindications for surgery or make the surgery more difficult or increase the risk of postoperative complications. In this context, the main important variations in portal venous system are as follows: trifurcation of the main portal vein into the left portal vein, the right anterior sectoral branch and to the right posterior sectoral branch; separate origin of the right posterior sectoral branch from the main portal vein prior to bifurcation; absence of the right portal truncus with the right front sectoral branch originating from the left portal vein; segment IV vein originating from the right portal vein; absence of the left portal vein (10). In the absence of the right portal truncus, the right lobe is fed by more than one

vein originating separately from the main portal vein and/or the left portal vein. In such cases, more than one portal vein anastomosis is required, and this makes the surgery longer and increases the risk of postoperative portal vein thrombosis (10). In the study carried out by Kamel et al. involving 40 potential donors, the frequency of the portal vein trifurcation was reported to be 15%, quadrifurcation 2.5%, and the right posterior sectoral branch originating from the main portal vein 2.5% (2). In our study involving 52 patients, these rates were 6%, 2% and 4%, respectively.

Although CT angiography findings were confirmed in all patients who were operated on, the relatively small number of surgically confirmed patients that would not allow reaching sound statistical results may be considered as a limitation of the study. However, multislice CT angiography can be seen as a promising method in obtaining the pre-operative mapping of the hepatic arterial, hepatic and portal venous systems of the potential donors prior to the right lobe transplantation and in non-invasively demonstrating the vascular variations

that might prevent the operation or make it more difficult.

References

1. Pannu HK, Maley WR, Fishman EK. Liver transplantation: preoperative CT evaluation. *Radiographics* 2001; 21:133-146.
2. Kamel IR, Kruskal JB, Keogan MT, Goldberg SN, Warmbrad G, Raptopoulos V. Multidetector CT of potential right-lobe liver donors. *AJR Am J Roentgenol* 2001; 177:645-651.
3. Bassignani MJ, Fulcher AS, Szucs RA, Chong WK, Prasad UR, Marcos A. Use of imaging for living donor liver transplantation. *Radiographics* 2001; 21:39-52.
4. Kamel IR, Kruskal JB, Keogan MT, Pomfret EA, Keogan MT, Warmbrand G, Raptopoulos V. Impact of multidetector CT on donor selection and surgical planning before living adult right lobe liver transplantation. *AJR Am J Roentgenol* 2001; 176:193-200.
5. Michels NA. *Blood Supply and Anatomy of the Upper Abdominal Organs with a Descriptive Atlas*. Philadelphia: Lippincott, 1955.
6. Winter TC, Freeny PC, Nghiem HV, Hommeyer SC, Barr D, Croghan AM, Coldwell DM. Hepatic arterial anatomy in transplantation candidates: evaluation with three-dimensional CT arteriography. *Radiology* 1995; 195:363-370.
7. Covey AM, Brody LA, Maluccio MA, Getrajdman GI, Brown KT. Variant hepatic arterial anatomy revisited: digital subtraction angiography performed in 600 patients. *Radiology* 2002; 224:542-547.
8. Deshpande RR, Heaton ND, Rela M. Surgical anatomy of segmental liver transplantation. *Br J Surg* 2002; 89:1078-1079.
9. Guiney MJ, Kruskal JB, Sosna J, Hanto DW, Goldberg SN, Raptopoulos V. Multi-detector row CT of relevant vascular anatomy of the surgical plane in split-liver transplantation. *Radiology* 2003; 229:401-407.
10. Mortele KJ, Cantisani V, Troisi R, de Hemptine B, Silverman SG. Preoperative liver donor evaluation: imaging and pitfalls. *Liver Transpl* 2003; 9:6-14.
11. Erbay N, Raptopoulos V, Pomfret EA, Kamel IR, Kruskal JB. Living donor liver transplantation in adults: vascular variants important in surgical planning for donors and recipients. *AJR Am J Roentgenol* 2003; 181:109-114.
12. Kamel IR, Raptopoulos V, Pomfret EA, Kruskal JB, Kane RA, Yam CS, Jenkins RL. Living adult right lobe liver transplantation: imaging before surgery with multidetector multiphase CT. *AJR Am J Roentgenol* 2000; 175:1141-1143.
13. Lavelle MT, Lee VS, Rofsky NM, Krinsky GA, Weinreb JC. Dynamic contrast-enhanced three-dimensional MR imaging of liver parenchyma: source images and angiographic reconstructions to define hepatic arterial anatomy. *Radiology* 2001; 218:389-394.
14. Hiatt JR, Gabbay J, Busuttill RW. Surgical anatomy of the hepatic arteries in 1000 cases. *Ann Surg* 1994; 220:50-52.
15. Kruskal JB, Raptopoulos V. How I do it: preoperative CT scanning for adult living right lobe liver transplantation. *Eur Radiol* 2002; 12:1423-1431.